



Clinical trials evaluating potential therapies for light chain (AL) amyloidosis

Eli Muchtar & Morie A. Gertz

To cite this article: Eli Muchtar & Morie A. Gertz (2017) Clinical trials evaluating potential therapies for light chain (AL) amyloidosis, Expert Opinion on Orphan Drugs, 5:8, 655-663, DOI: [10.1080/21678707.2017.1341834](https://doi.org/10.1080/21678707.2017.1341834)

To link to this article: <https://doi.org/10.1080/21678707.2017.1341834>



Accepted author version posted online: 10 Jun 2017.
Published online: 19 Jun 2017.



Submit your article to this journal [↗](#)



Article views: 44

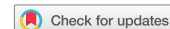

View related articles [↗](#)



View Crossmark data [↗](#)

REVIEW



Clinical trials evaluating potential therapies for light chain (AL) amyloidosis

Eli Muchtar and Morie A. Gertz

Division of Hematology, Mayo Clinic, Rochester, MN, USA

ABSTRACT

Introduction: The field of systemic amyloidosis is experiencing major advances in diagnostic and prognostic methods coupled with a growing availability in treatment options.

Areas covered: Treatment of AL amyloidosis traditionally targeted the clonal plasma cells, in order to block further production of amyloidogenic light chains. Currently, a research focus is placed on targeting the already formed amyloid deposits using monoclonal antibodies against epitopes on such deposits. Encouraging results were obtained from the three investigated antibodies: NEOD001, 11-1F4 and anti-SAP, but further validation is required before these antibodies can be commercialized. In this paper, we review the current active clinical research in AL amyloidosis, which includes the monoclonal antibodies targeting amyloid deposits, daratumumab, Venetoclax, doxycycline, green tea, pomalidomide, carfilzomib and ixazomib.

Expert opinion: Monoclonal antibodies, targeting either the amyloid deposits or the plasma cell compartment will likely be integrated into routine treatment practice given their encouraging results and minimal toxicity in the fragile population of AL amyloidosis. Other therapeutic options hold promise to the field as well, but toxicity will likely challenge their routine use. Early recognition remains the best option for outcome enhancement.

ARTICLE HISTORY

Received 27 April 2017
Accepted 9 June 2017

KEYWORDS

Monoclonal antibody;
research; clinical-trials;
amyloid

1. Introduction

Immunoglobulin light chain (AL) amyloidosis is a systemic disease, characterized by deposition of fibrillary material termed amyloid in body tissues (Figure 1). The amyloid deposits are composed of several proteins common to all deposits but vary in the culprit subunit protein, which requires amyloid typing [1]. In AL amyloidosis, the culprit protein is light chains, immunoglobulin subunits, secreted by monoclonal plasma cells in the bone marrow, usually of low proliferation rate. Since these deposits are resistant to degradation, amyloid deposits accumulate over time, leading to progressive organ dysfunction. Cardiac amyloidosis is the most common organ to be involved and is the leading cause of death, due to electromechanical dissociation, lethal arrhythmia, or end-stage heart failure [2]. Early death rate is high, reaching over 30% in the first 6 months from diagnosis for patients with advanced disease [3].

One of the prominent challenges of this disease is early recognition. Diagnosis is delayed due to the nonspecific symptoms associated with the disease [4]. The delay in diagnosis results in progressive organ dysfunction and failure of delivering effective therapy due to frailty, organ impairment, and poor treatment tolerance. In recent years, however, AL amyloidosis has witnessed significant improvements in screening and diagnostic techniques which facilitate an earlier diagnosis. The serum free light chain assay is a readily accessible test that is able to detect small abnormalities in light chain production in the majority of patients and serves as an excellent screening test [5]. Another important advance is the introduction of

mass spectrometry analysis to accurately type the amyloidogenic protein within the amyloid deposit [6]. Enhanced response assessment using the serum free light chain assay allowed for setting evidence-based treatment goals [7]. The emergence of effective therapies for fit patients in the form of autologous stem cell transplantation (ASCT) and standard regimens for the sicker population is responsible for the significant improvement in survival in the past 15 years [3].

Treatment options are still limited and often follow regimens used for treatment of multiple myeloma (MM). MM and AL amyloidosis only partially overlap and an effective treatment in MM may not be as effective in AL amyloidosis due to reduced tolerability or different disease biology. Immunomodulatory drugs (IMiDs), excellent agents in MM, are poorly tolerated in AL amyloidosis with suboptimal responses [8]. Genetic abnormalities differ between the two diseases and may impact response to therapy [9].

In this review, we will summarize the potential new treatments for AL amyloidosis which currently are being investigated in clinical trials. Currently ongoing trials are summarized in Table 1. As understanding of the disease improves and with the emergence of new therapies, this will result in a need to optimize drug utilization while avoiding unwanted toxicities.

2. Potential therapies for light chain (AL) amyloidosis

Schematic illustration of the options discussed in the section below is depicted in Figure 2.

Article highlights

- AL amyloidosis has seen improvement in patient outcomes following the recent introduction of novel therapies
- New therapies targeting the amyloidogenic plasma cells further expand the armamentarium and should provide further improvement in patient outcome
- Monoclonal antibodies targeting the amyloid deposits represent a novel approach for AL amyloidosis management. These antibodies demonstrated encouraging results in early phase clinical trials, and may be incorporated into routine practice in the future, pending the results of phase 2/3 trials.
- With the emergence of effective therapies, the importance of early diagnosis cannot be overemphasized

This box summarizes key points contained in the article.

2.1. Monoclonal antibodies targeting the amyloid deposits

2.1.1. NEOD001

NEOD001 is an investigational humanized monoclonal antibody, targeting two components of amyloid: soluble aggregates of circulating amyloid and insoluble amyloid deposits [10]. The binding of NEOD001 to amyloid neutralizes the soluble form and facilitates the phagocytic clearance of the insoluble amyloid deposits (Figure 3). NEOD001 was evaluated in a phase I/II trial [11]. Twenty-seven patients with prior anti-plasma cell treatment who achieved at least partial response and had persistent organ dysfunction were enrolled to receive a monthly 1–2-h infusion of the investigational antibody. There were no infusion-related reactions, treatment-related serious adverse events, or drug discontinuation. Cardiac and renal responses were seen in approximately 60% of

the evaluable patients. In the extension cohort of this study, a peripheral neuropathy response was achieved in 82% of patients.

Currently, two trials are currently ongoing worldwide. The first one is the PRONTO trial (NCT02632786), a phase 2b, randomized, placebo-controlled trial in previously treated AL amyloidosis and persistent cardiac dysfunction. One hundred patients are planned to be enrolled into this trial and receive a monthly infusion of NEOD001 24 mg/kg or placebo with the primary objective being cardiac best response as measured by NT-proBNP. The second study is the VITAL trial (NCT02312206), a phase 3 study, which has a recruitment goal of 236 patients, estimated to be reached in mid-2018. This randomized study aims to evaluate the efficacy and safety of NEOD001 versus placebo in the setting of standard chemotherapy in untreated AL amyloidosis with cardiac involvement. All patients receive bortezomib-based chemotherapy for duration at the discretion of the treating physician. Patients receive monthly infusion of the investigational antibody or placebo. The primary outcome measure is time to composite of all-cause mortality or cardiac hospitalization as well as secondary surrogate outcomes such as change in the 6-min walk test (clinical response), cardiac response, and renal response. An extension phase is offered to all patients after 15 months on the trial, to receive monthly NEOD001 infusions for up to additional 12 months (NCT02613182). The RAIN trial is a phase 2b study expected to open during 2017. This trial will investigate the use of NEOD001 in patients who achieved hematological response with persistent renal impairment.

2.1.2. 11-1F4 monoclonal antibody

11-1F4 monoclonal antibody is a chimeric antibody, targeting the misfolded light chains in the amyloid fibrils but does not

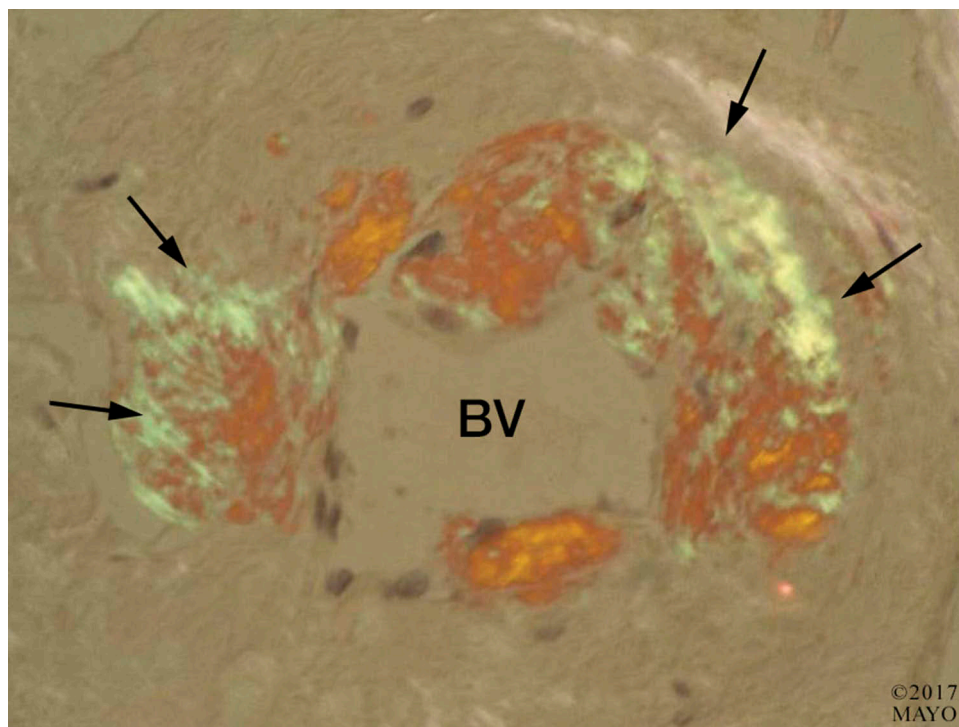


Figure 1. Congo-red stain of bone marrow biopsy (X1000). A deposition of fibrillary material in the walls of a blood vessel (BV) can be noted, demonstrating apple-green birefringence under polarized light (arrows), a pathognomonic hallmark of amyloid deposits.

Table 1. Summary of ongoing clinical trials in AL amyloidosis.

serial	NCT number	Trial design	Trial arm(s)	Number of planned recruitment	Expected date for primary outcome analysis
Monoclonal antibodies					
1	NCT02632786 (Pronto trial)	Phase 2b, randomized, double-blind, placebo-controlled	NEOD001 compared to placebo in patients with AL amyloidosis who had a hematologic response to previous treatment and have persistent cardiac dysfunction	100	January 2018
2	NCT02312206 (VITAL trial)	Phase 3, randomized, double-blind, placebo-controlled	NEOD001 plus standard chemotherapy compared to placebo plus standard chemotherapy in patients with newly diagnosed AL amyloidosis	236	August 2018
3	NCT02245867	Phase 1, single-arm study	To examine the tolerance, safety, pharmacokinetics, and clinical benefit of 11-1F4 monoclonal antibody in subjects with previously treated AL amyloidosis	42	September 2017
4	NCT03044353	Phase 2, open-label, single-arm study	Three groups of cardiac amyloidosis patients, each receives monthly infusion of anti-SAP monoclonal antibody: Group 1: ATTR cardiac amyloidosis Group 2: previously treated cardiac AL amyloidosis Group 3: newly diagnosed cardiac AL amyloidosis receiving standard chemotherapy	50	July 2020
5	NCT02816476	Phase 2, single-arm study	Daratumumab for patients with AL amyloidosis who did not achieve a VGPR or better to previous therapy	40	June 2018
6	NCT02841033	Phase 1/2 study, single arm	Daratumumab for previously treated AL amyloidosis, requiring therapy	25	August 2018
Oral agents					
7	NCT03000660	Phase 1, single-arm study	Tolerability and safety of venetoclax (ABT-199) plus dexamethasone in patients with relapsed/refractory AL amyloidosis	25	January 2019
8	NCT02207556	Phase 2, single-arm study	Safety and efficacy of adding doxycycline (up to 12 months) to standard therapy in patients with AL amyloidosis	30	September 2017
9	NCT02015312	Phase 2, single-arm study	Efficacy and safety of EGCG in patients with cardiac AL amyloidosis	38	November 2017
10	NCT01659658	Phase 3, Randomized, controlled, open-label	Ixazomib plus dexamethasone compared to five different oral regimens in patients with relapsed/refractory AL amyloidosis who did not receive prior proteasome inhibitor	248	September 2018

NCT: National clinical trial; VGPR: very good partial response.

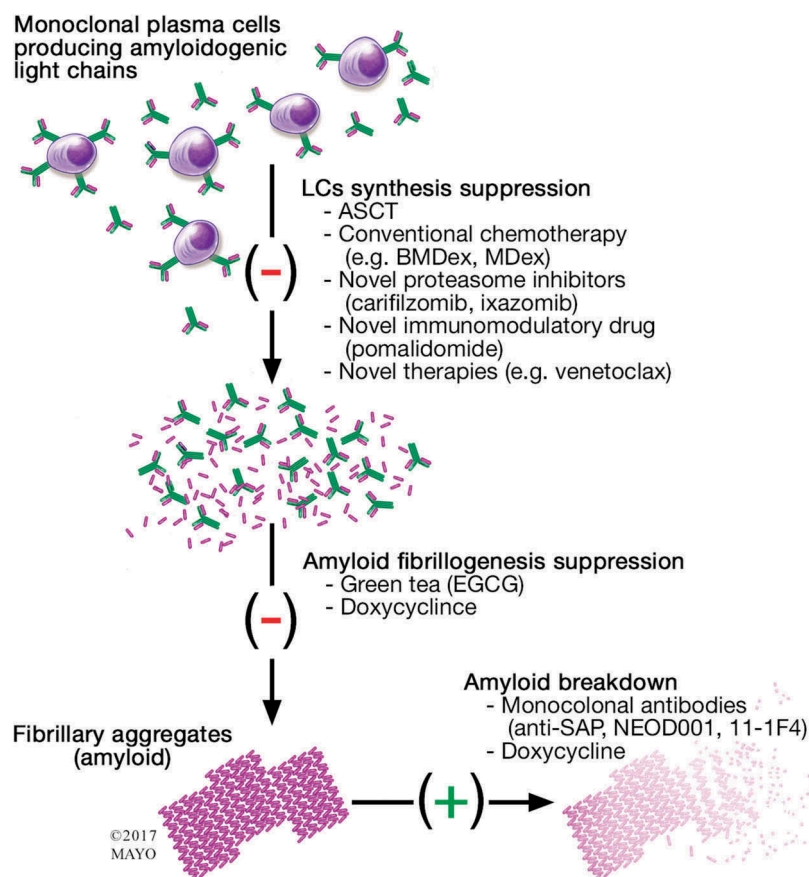
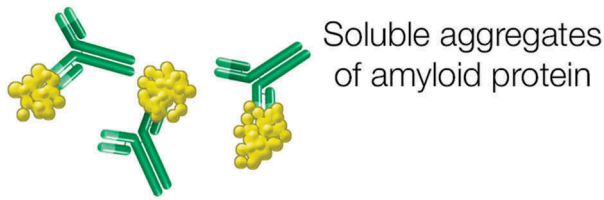


Figure 2. Schematic presentation of the therapeutic options under clinical investigation in AL amyloidosis. ASCT: Autologous stem cell transplantation; BMDex: Bortezomib-melphalan-dexamethasone; MDex: Melphalan-dexamethasone; SAP: Serum amyloid P.

(a) Neutralization



(b) Clearance

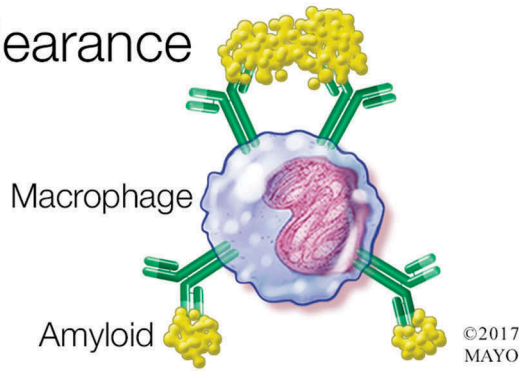


Figure 3. Proposed mechanisms of action of NEOD001. (a). Neutralization of circulating amyloid aggregates. (b). Facilitation of phagocytic clearance of insoluble amyloid deposits.

react with the circulating, soluble free light chains. The antibody was formed against a K4 light chain but is reactive against both K and λ light chains, targeting a conformational epitope present on both light chains within the amyloid deposits [12]. In a mouse amyloidoma model, administration of 11-1F4 antibody led to an inflammatory response, which resulted in an enhanced phagocyte-mediated removal of the deposits [13].

11-1F4 chimeric antibody is now being investigated in phase I/II clinical trial among relapsed refractory AL patients with partial response or better to anti-plasma cell therapy (NCT02245867). The phase I part was explored in two infusion schedules: single infusion and 4 weekly infusions. Preliminary results from the phase I trial with 19 patients are available. Treatment was tolerated up to the maximal tested dose of 500 mg/m², with no significant adverse events related to the drug infusion. A rash developed in two patients, in one of whom a skin biopsy from a lesion demonstrated unrecognized skin amyloid deposits. There was a positive stain for the infused antibody and an accompanying neutrophilic infiltrate. Organ responses were seen in 63% of patients with single antibody infusion and in 83% of patients in the 4 weekly infusion schedule [14]. The study is in phase 2 recruitment as of early 2017.

2.1.3. Serum amyloid P antibody

Serum amyloid P (SAP) is a glycoprotein that constitutes part of all amyloid deposits of any origin and has a role as a deposit stabilizer, providing resistance to proteolytic degradation. It is an attractive target, as it binds to amyloid deposits regardless of type. Its administration requires depleting circulating SAP using an oral agent called CPHPC in order to prevent antibody binding to serum SAP (CPHPC mediates cross-linking of SAP molecules which facilitates their hepatic clearance [15]). The

antibody was tested in a mouse model and demonstrated a phagocyte-mediated removal of amyloid visceral deposits [16]. A phase I trial using a single serum amyloid P antibody (anti-SAP) infusion showed a reduction in amyloid deposits, mainly hepatic, in those who received the higher antibody dose [17]. Cardiac amyloidosis patients, the most common and clinically significant organ involved in AL amyloidosis, were excluded from participation in this trial. A phase 2 study, not yet in a recruitment phase, is planned to assess monthly infusion of anti-SAP in three cohorts of cardiac amyloidosis patients: transthyretin (ATTR) amyloidosis, previously treated AL amyloidosis, newly diagnosed AL amyloidosis in conjunction with chemotherapy (NCT03044353).

2.2. Monoclonal antibody targeting the plasma cells: daratumumab

Daratumumab is a humanized IgG-K monoclonal antibody which targets CD38, a surface marker found on plasma cells. It has single-agent activity in relapsed refractory myeloma [18–20] and a synergistic effect in combination with proteasome inhibitor [21] or with an IMiD [22,23]. Its toxicity profile is low, mainly infusion reactions at initial administration. This agent should be an attractive agent in AL amyloidosis, given its single-agent activity and low toxicity profile [24]. The first report on daratumumab use in AL amyloidosis included two myeloma patients who developed extensive AL amyloidosis during the course of their disease [25]. Daratumumab was infused at the prescribed dose and schedule for myeloma and was able to achieve a rapid normalization of the involved light chain. This is a remarkable observation in these patients, given their lack of light chain normalization with prior therapies, including proteasome inhibitors, an IMiD, dexamethasone, and stem cell transplant. Treatment was well tolerated without significant toxicities. Two additional reports in abstract form are available, with 18 and 7 patients each. In the first report, daratumumab yielded a response in 88% of patients, including deep response (\geq very good partial response [VGPR] or complete response [CR]) in 41% [26]. In a subset of 12 patients with amyloid cardiomyopathy in that study, 83% achieved a response (60% VGPR/CR) and some had a cardiac response [27]. In the second report, in which all patients had prior ASCT, hematological response was achievable in all patients (71% as deep response) [28]. Infusion reaction occurred in most patients but mostly was mild in nature. These data are encouraging and daratumumab is likely to have an important role in the management of AL amyloidosis. Currently, two phase 2 trials assessing daratumumab in AL amyloidosis are being held in patients with previously treated AL amyloidosis (NCT02816476, NCT02841033).

2.3. Venetoclax

Venetoclax is a selective small molecule BCL-2 inhibitor. It is approved for progressive chronic lymphocytic leukemia with deletion of chromosome 17p [29]. In MM, venetoclax has shown encouraging single-agent activity in the relapsed refractory setting, primarily for patients with translocation (11;14) [30]. This drug is potentially a very attractive agent

for AL amyloidosis, given its impressive single-agent activity in myeloma with t(11;14). t(11;14) is seen in approximately half of AL amyloidosis patients and as bortezomib and IMiDs have inferior outcomes in AL amyloidosis with t(11;14) [9], venetoclax may bring a genetically tailored approach to the treatment of AL amyloidosis. It is an oral medication, well tolerated with a mild adverse events profile and no apparent cardiac toxicity. This agent is currently being investigated in a phase I trial in combination with dexamethasone for patients with relapsed or refractory AL amyloidosis (NCT03000660).

2.4. Doxycycline

Doxycycline has been shown *in vitro* to inhibit the formation of amyloid fibrils and to disaggregate formed fibrils by disrupting the beta-pleated structure of the amyloid fibrils [31,32]. Two studies have demonstrated a survival advantage for doxycycline in patients with AL amyloidosis. The first study from the Mayo clinic examined the survival in patients following stem cell transplantation based on biological randomization of the anti-infective prophylaxis in the first year following ASCT [33]. Of 455 evaluated patients, 77% received oral penicillin which is the standard of care for antibacterial prophylaxis following ASCT at Mayo clinic while 23% received oral doxycycline as the prophylaxis agent due to a history of penicillin allergy. Among patients who achieved hematological response to ASCT, oral doxycycline was associated with a longer overall survival (median not reached compared to 161 months, respectively; $P = 0.04$). The second study was a case-control study involving AL amyloidosis patients who were treated with standard chemotherapy [34]. Thirty patients treated with doxycycline from the start of therapy were matched to controls ($n = 73$) who did not receive doxycycline as part of their management. All patients had cardiac amyloidosis and were matched based on age, cardiac stage, N-terminal brain natriuretic peptide (NT-proBNP), and light chain burden. Patients were treated with doxycycline 100 mg bid for a median duration of 6 months; 10% discontinued doxycycline for adverse events (photosensitivity, nausea). Bortezomib was the initial regimen in over 70% of patients. The response rate was significantly higher in the doxycycline group compared to the control group (93% vs. 59%; $P = 0.001$), driven mainly by a higher CR rate (56% vs. 35%). Cardiac response was seen in 60% of patients in the doxycycline group compared to 18% in the control group. A survival advantage was noted in the doxycycline group compared to the control group (12-month survival 82% vs. 53%; $P < 0.001$). This study suggests that doxycycline may reduce early mortality in the non-transplant setting and enable more patients to achieve hematological and organ response with effective therapy, which translates into survival benefit. Currently, two phase II trials for the evaluation of doxycycline in AL amyloidosis are accruing in the USA (NCT02207556, NCT01677286). The use of doxycycline should await validation in a randomized trial. Doxycycline tolerability in AL patients may be a major barrier given the side-effect profile of this drug [35].

2.5. Green tea

The first description of the effect of green tea in AL amyloidosis is a decade old. Daily consumption of green tea in large

volume (1.5–2 l daily) by an AL patient resulted in improved cardiac functional parameters, a reduction of 4 mm in septal thickness within 11 months and improved quality of life [36]. This initial observation was followed by a case-control study with 11 cardiac AL patients who consumed green tea either by drinking large volumes daily or by consuming commercially available green tea extract capsules [37]. A functional class improvement was noted in most patients as well as an average reduction of 2 mm in septal thickness and 24% reduction in left ventricular mass over a 6-month period. Improvements were not noted in 22 historical controls. Echocardiographic changes can be observer dependent, while cardiac biomarkers remained unchanged during follow-up period in both groups. The active ingredient in green tea which is thought to exert its beneficial effect in cardiac amyloidosis is epigallocatechin-gallate (EGCG). EGCG is a naturally derived phenol enriched in green tea, which interferes *in vitro* with the aggregation of the amyloidogenic proteins [38]. Recently, a phase 2 randomized trial of 57 previously treated patients who required systemic chemotherapy was reported [39]. The treatment arm received green tea extract capsules three times daily ($n = 36$), while the second arm was under observation without placebo ($n = 21$). Both groups were given melphalan-based chemotherapy. Blood concentrations of EGCG were higher in the treatment arm than in the observation arm. Adverse events were higher in the treatment arm and 4/36 patients discontinued the investigational treatment due to adverse effects. One death was noted in each arm. There was no difference in the depth of the hematological response or in organ response parameters between the two arms. A single-center randomized trial is underway to assess the significance of green tea extract in the management of AL amyloidosis (NCT02015312).

2.6. Pomalidomide

Pomalidomide is an immunomodulatory (IMiD) agent, a derivative of the parent drug thalidomide. It is an active agent in MM, both in the relapsed refractory setting as well as in newly diagnosed patients. It is active in the face of refractoriness to thalidomide and lenalidomide [40]. IMiDs, however, are less well-tolerated agents in AL amyloidosis. Given their poor tolerance, modest activity and its effect causing a rise in the cardiac biomarker, NT-proBNP [8], resulted in the use of an IMiD as first-line treatment in our institution of less than 10% and declined with time [3]. However, the progressive nature of AL amyloidosis and paucity of effective standard therapies has led to the investigation of pomalidomide in previously treated AL patients. The first trial included 33 patients, the majority of which had cardiac involvement (82%) [41]. Patients were treated with pomalidomide 2 mg orally daily along with dexamethasone 40 mg orally once weekly. Treatment was until progression, unacceptable toxicity, or death. The hematological response rate was 48%. Time to response was close to 2 months and duration of response was 19 months. The median OS was 27.9 months and 76% survived 1 year. Two additional trials demonstrated comparable results [42,43]. These trials provide the feasibility of escalating the pomalidomide to 4 mg daily, although a third of the patients required dose modification due to adverse events. Responses in

patients with prior lenalidomide exposure were seen in all trials. Two of the three trials reported that like other IMiDs, pomalidomide is associated with paradoxical elevation in NT-proBNP, which was not associated with worsening of cardiac function or symptoms. The nature of this phenomenon is unclear and unless associated with symptoms, other signs of cardiac decompensation or concern for organ progression (i.e. no hematological response seen) should not result in a change in therapy.

One trial is currently assessing pomalidomide and dexamethasone as frontline therapy in AL amyloidosis. In our experience, pomalidomide is more tolerable in AL amyloidosis than other IMiDs, at the 2-mg daily dose.

2.7. Proteasome inhibitors

Plasma cells (PCs) recovered from AL patients showed a higher sensitivity to proteasome inhibitors compared to PCs obtained from myeloma patients [44]. This sensitivity is thought to be induced by intracellular stressors imposed by the amyloidogenic light chains. This *in-vitro* finding may explain the better responses seen with bortezomib compared to other standard chemotherapies in AL patients.

2.7.1. Bortezomib

Bortezomib, the first proteasome inhibitor in use, is the most common agent used in the United States for newly diagnosed AL amyloidosis patients ineligible for ASCT. Its current investigation in AL amyloidosis is focused on its use as pre-ASCT induction, in combination with high-dose melphalan during ASCT and as consolidation following ASCT. Other proteasome inhibitors have been introduced into the treatment schemes in MM, namely carfilzomib and ixazomib. These agents are evaluated for their safety and efficacy in AL amyloidosis.

2.7.2. Carfilzomib

Carfilzomib is second-generation proteasome inhibitor that has been approved for relapsed/refractory MM since summer 2012. It is given intravenously on two consecutive days, 3 out of 4-week cycle. The drug is traditionally infused with pre- and post-hydration to prevent renal toxicity [45]. This challenging schedule and associated fluid infusion make carfilzomib a less attractive agent for AL amyloidosis compared with the parent drug bortezomib. In addition, carfilzomib is associated with cardiac toxicity in approximately 10% of myeloma patients [46,47]. Therefore, the risk of enhanced cardiac toxicity in AL patients is a concern. Twenty-eight patients with a median of two prior therapies were enrolled into a phase 1, dose-escalating trial [48]. The most commonly involved organs were renal (64%) and heart (50%). The maximal tolerated dose was 20 mg/m² on days 1, 2 of cycle one followed by 36 mg/m² for all remaining doses (20/36 mg/m² schedule), lower than the MTD in myeloma patients (56 mg/m²) [45]. Cardiopulmonary toxicity was seen in several patients: two patients experienced ventricular tachycardia, one of whom required electrical shock; three patients with decreased ejection fraction/congestive heart failure; three patients with hypertension; one patient with hypotension and one patient with hypoxemia. NT-proBNP increase meeting criteria for organ progression occurred in 11/28 patients, although

differentiating toxicity from organ progression is challenging in this setting. Hematological response was seen in over 50% of patients (15/28), while 5 patients had organ responses. With a median follow-up of 16 months, two patients died. A phase 2 study assessing carfilzomib and thalidomide in relapsed AL amyloidosis is planned (NCT02545907).

2.7.3. Ixazomib

Ixazomib is a second-generation proteasome inhibitor. It is given orally, once weekly for 3 weeks out of a 4-week cycle, at a recommended dose of 4 mg weekly [49]. It is well tolerated with minimal toxicity. The drug was evaluated in 22 AL patients with a median of three prior regimens [50]. Sixteen patients had received prior bortezomib and six patients were bortezomib naïve. Toxicity was manageable and there were no reports of cardiorespiratory events. Deep hematological responses (\geq VGPR) occurred in 43% of patients and were associated with cardiac response and longer progression-free survival. An international phase 3 randomized study is underway, assessing ixazomib plus dexamethasone compared to physician choice (from five various options) in patients with relapsed/refractory AL amyloidosis not previously exposed to proteasome inhibitors (NCT01659658).

3. Expert opinion

The field of AL amyloidosis is facing significant changes in diagnosis, prognostication, and treatment availability. Sensitivity of the screening methods for AL amyloidosis increased with the emergence of the serum free light chains assay, raising the possibility of earlier diagnosis. Prognostic systems have been developed [51–53] and stringent eligibility criteria for stem cell transplant have enhanced transplant outcome [54]. New anti-plasma cell agents have been introduced in the past decade and broadened treatment options beyond alkylators and glucocorticoids, which dominated the amyloidosis landscape for close to 30 years (Figure 4) [55]. Treatment toxicity in AL patients may differ from the toxicity profile seen in MM. Outcome following ASCT in amyloidosis patients is significantly better than transplant outcome in myeloma [56]. On the contrary, while IMiDs are excellent agents in myeloma (mainly for lenalidomide and pomalidomide), they achieve only modest benefits in AL amyloidosis. Therefore, a careful and dedicated exploration of new treatments should always be performed in an AL population, even after the drug has been shown to be active and safe in myeloma patients.

Monoclonal antibodies are likely to become a key component in the management of AL amyloidosis. Monoclonal antibodies are safe, well tolerated with no cardiac toxicity, a key factor in this disease. Daratumumab has a single-agent activity and in our experience has produced remarkable results in patients who were refractory to prior lines of therapy. It is likely to be used in combination with other agents, although it is unclear what the optimal combination and whether daratumumab should become part of initial therapy. Monoclonal antibodies targeting amyloid deposits are showing promising results. The exact setting in which these antibodies will be used is an important question. Data come from patients who achieved hematological response and had persistent organ dysfunction. The VITAL trial in

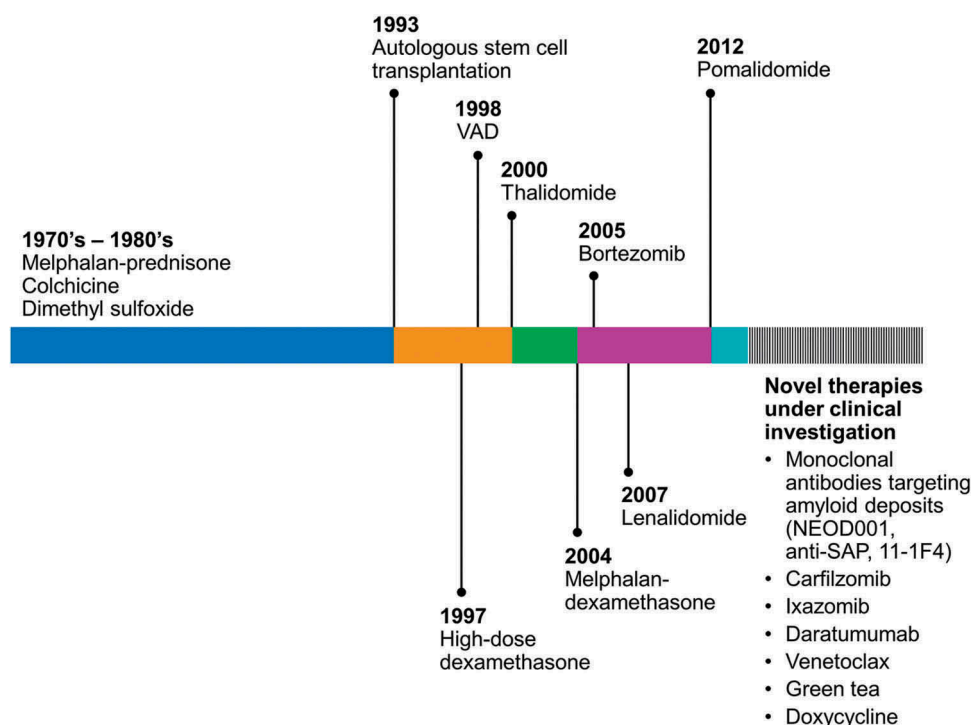


Figure 4. Treatment of AL amyloidosis over the past 50 years, demonstrating an expansion in effective therapies since the beginning of the millennium. Therapies under advanced clinical trials are listed in the fragmented bar (SAP: Serum amyloid A; VAD: Vincristine-adriamycin-dexamethasone).

which NEOD001 is given upfront with bortezomib-based therapy and compared to placebo and bortezomib is likely to provide the best data on the role of monoclonal antibodies targeting amyloid deposits.

Ease of access to green tea and doxycycline is a barrier to testing these agents in good-quality trials. We do not see the available data as sufficient to recommend these agents. Patients who use green tea should be advised on its potential negative interaction with bortezomib *in vitro* [57] and those who use doxycycline should be advised on photosensitivity and gastrointestinal disturbances associated with its use.

The new treatments developed for AL amyloidosis are encouraging and we anticipate that outcomes for AL amyloidosis which improved in the past decade will continue to improve in the coming years. With the ability to achieve deep hematological response in the majority of patients, a focus on enhancing organ recovery is required. Monoclonal antibodies targeting the amyloid deposits will likely play a major role. However, early recognition remains the best way to reduce morbidity, organ dysfunction, and death from the disease.

We consider autologous stem cell transplant as a major treatment modality in this disease and it is likely to remain as such for the coming years. ASCT provides the best long-term disease control and longer survival for those who are candidates for this intensive treatment (a third of the patients in our referral population) [3]. Therefore, outside a clinical trial setting, our recommendation for moving forward with ASCT (with or without induction chemotherapy) for eligible patients has not changed. With stricter eligibility criteria, the transplant-related mortality is 2% in our center [3], similar to the mortality rate in the myeloma population. Therefore, ASCT is safe when performed in specialized centers and produces the best long-term outcome (4-year survival 91%). Currently, all investigated agents

have not reached a point of changing current standard treatment for transplant-ineligible patients. Those patients should be treated with bortezomib-based or melphalan-based treatment, with the goal of achieving deep response (\geq VGPR) in order to maximize their organ function and prognosis.

In summary, AL amyloidosis is transforming from a disease with limited treatment options and high morbidity and mortality to a new era in which patients at different stages can be offered effective therapies and experience improvement in outcome. The rarity of the disease and its complexity should favor evaluation and management at specialized centers. Early diagnosis should remain an important goal to increase chances of recovery and prolonged survival.

Funding

This paper was not funded

Declaration of interest

M Gertz has received honoraria not related to publication of this manuscript from Celgene, Prothena, and Amgen. The authors have no relevant affiliations or financial involvement with any organization or entity with a financial interest in or financial conflict with the subject matter or materials discussed in the manuscript. This includes employment, consultancies, honoraria, stock ownership or options, expert testimony, grants or patents received or pending, or royalties.

References

Papers of special note have been highlighted as either of interest (*) or of considerable interest (**) to readers.

1. Sipe JD, Benson MD, Buxbaum JN, et al. Amyloid fibril proteins and amyloidosis: chemical identification and clinical classification

- International Society of Amyloidosis 2016 Nomenclature Guidelines. *Amyloid*. 2016;23:209–213.
2. Grogan M, Dispenzieri A. Natural history and therapy of AL cardiac amyloidosis. *Heart Fail Rev*. 2015;20:155–162.
 3. Muchtart E, Gertz MA, Kumar SK, et al. Improved outcomes for newly diagnosed AL amyloidosis over the years 2000–2014: cracking the glass ceiling of early death. *Blood*. 2017.
 4. Muchtart E, Buadi FK, Dispenzieri A, et al. Immunoglobulin light-chain amyloidosis: from basics to new developments in diagnosis, prognosis and therapy. *Acta Haematol*. 2016;135:172–190.
 5. Gertz MA, Lacy MQ, Dispenzieri A, et al. Amyloidosis: diagnosis and management. *Clin Lymphoma Myeloma*. 2005;6:208–219.
 - **The first trial to demonstrate the potential benefit of monoclonal antibody-targeting the amyloid deposits in improving organ function in AL amyloidosis.**
 6. Vrana JA, Gamez JD, Madden BJ, et al. Classification of amyloidosis by laser microdissection and mass spectrometry-based proteomic analysis in clinical biopsy specimens. *Blood*. 2009;114:4957–4959.
 7. Palladini G, Dispenzieri A, Gertz MA, et al. New criteria for response to treatment in immunoglobulin light chain amyloidosis based on free light chain measurement and cardiac biomarkers: impact on survival outcomes. *J Clin Oncol*. 2012;30:4541–4549.
 8. Jelinek T, Kufova Z, Hajek R. Immunomodulatory drugs in AL amyloidosis. *Crit Rev Oncol Hematol*. 2016;99:249–260.
 9. Muchtart E, Dispenzieri A, Kumar SK, et al. Interphase fluorescence in-situ hybridization (iFISH) in untreated AL amyloidosis has an independent prognostic impact by abnormality type and treatment category. *Leukemia*. 2016.
 10. Renz M, Torres R, Dolan PJ, et al. 2A4 binds soluble and insoluble light chain aggregates from AL amyloidosis patients and promotes clearance of amyloid deposits by phagocytosis dagger. *Amyloid*. 2016;23:168–177.
 11. Gertz MA, Landau H, Comenzo RL, et al. First-in-human phase I/II study of NED001 in patients with light chain amyloidosis and persistent organ dysfunction. *J Clin Oncol*. 2016;34:1097–1103.
 12. Solomon A, Weiss DT, Wall JS. Immunotherapy in systemic primary (AL) amyloidosis using amyloid-reactive monoclonal antibodies. *Cancer Biother Radiopharm*. 2003;18:853–860.
 13. Solomon A, Weiss DT, Wall JS. Therapeutic potential of chimeric amyloid-reactive monoclonal antibody 11-1F4. *Clin Cancer Res*. 2003;9:3831S–3838S.
 14. Edwards CV, Gould J, Langer AL, et al. Analysis of the phase 1a/b study of chimeric fibril-reactive monoclonal antibody 11-1F4 in patients with AL amyloidosis. *Blood*. 2016;128:643–643.
 15. Pepys MB, Herbert J, Hutchinson WL, et al. Targeted pharmacological depletion of serum amyloid P component for treatment of human amyloidosis. *Nature*. 2002;417:254–259.
 16. Bodin K, Ellmerich S, Kahan MC, et al. Antibodies to human serum amyloid P component eliminate visceral amyloid deposits. *Nature*. 2010;468:93–97.
 17. Richards DB, Cookson LM, Berges AC, et al. Therapeutic clearance of amyloid by antibodies to serum amyloid P component. *N Engl J Med*. 2015;373:1106–1114.
 - **A pioneering study on the use of a monoclonal antibody-targeting amyloid deposits.**
 18. Usmani SZ, Weiss BM, Plesner T, et al. Clinical efficacy of daratumumab monotherapy in patients with heavily pretreated relapsed or refractory multiple myeloma. *Blood*. 2016;128:37–44.
 19. Lonial S, Weiss BM, Usmani SZ, et al. Daratumumab monotherapy in patients with treatment-refractory multiple myeloma (SIRIUS): an open-label, randomised, phase 2 trial. *Lancet*. 2016;387:1551–1560.
 20. Lokhorst HM, Plesner T, Laubach JP, et al. Targeting CD38 with daratumumab monotherapy in multiple myeloma. *N Engl J Med*. 2015;373:1207–1219.
 21. Palumbo A, Chanan-Khan A, Weisel K, et al. Daratumumab, bortezomib, and dexamethasone for multiple myeloma. *N Engl J Med*. 2016;375:754–766.
 22. Plesner T, Arkenau HT, Gimsing P, et al. Phase 1/2 study of daratumumab, lenalidomide, and dexamethasone for relapsed multiple myeloma. *Blood*. 2016.
 23. Dimopoulos MA, Oriol A, Nahi H, et al. Daratumumab, lenalidomide, and dexamethasone for multiple myeloma. *N Engl J Med*. 2016;375:1319–1331.
 24. Xia C, Ribeiro M, Scott S, et al. Daratumumab: monoclonal antibody therapy to treat multiple myeloma. *Drugs Today*. 2016;52:551–560.
 25. Sher T, Fenton B, Akhtar A, et al. First report of safety and efficacy of daratumumab in 2 cases of advanced immunoglobulin light chain amyloidosis. *Blood*. 2016;128:1987–1989.
 26. Kaufman G, Witteles R, Wheeler M, et al. Daratumumab yields rapid hematologic responses in patients with heavily pretreated, relapsed AL amyloidosis. *Clin Lymphoma Myeloma Leuk*. 2016;16(suppl 2):S75.
 27. Kaufman G, Witteles R, Wheeler M, et al. Hematologic responses and cardiac organ improvement in patients with heavily pretreated cardiac immunoglobulin light chain (AL) amyloidosis receiving daratumumab. *Blood*. 2016;128:4525–4525.
 28. Weiss BM, Cohen AD, Dember LM, et al. Clinical experience with daratumumab in AL amyloidosis and MM with AL amyloidosis. Presented at the XVth International Symposium on Amyloidosis; 2016 July 3–7; Uppsala; 2016.
 29. Itchaki G, Brown JR. The potential of venetoclax (ABT-199) in chronic lymphocytic leukemia. *Ther Adv Hematol*. 2016;7:270–287.
 30. Kumar S, Vij R, Kaufman JL, et al. Venetoclax monotherapy for relapsed/refractory multiple myeloma: safety and efficacy results from a phase I study. *Blood*. 2016;128:488–488.
 31. Giorgetti S, Raimondi S, Pagano K, et al. Effect of tetracyclines on the dynamics of formation and deconstruction of beta2-microglobulin amyloid fibrils. *J Biol Chem*. 2011;286:2121–2131.
 32. Ward JE, Ren R, Toraldo G, et al. Doxycycline reduces fibril formation in a transgenic mouse model of AL amyloidosis. *Blood*. 2011;118:6610–6617.
 33. Kumar SK, Dispenzieri A, Lacy MQ, et al. Doxycycline used as post transplant antibacterial prophylaxis improves survival in patients with light chain amyloidosis undergoing autologous stem cell transplantation. *Blood*. 2012;120:3138–3138.
 34. Wechalekar AD, Whelan C. Encouraging impact of doxycycline on early mortality in cardiac light chain (AL) amyloidosis. *Blood Cancer J*. 2017;7:e546.
 35. Sloan B, Scheinfeld N. The use and safety of doxycycline hyclate and other second-generation tetracyclines. *Expert Opin Drug Saf*. 2008;7:571–577.
 36. Hunstein W. Epigallocatechin-3-gallate in AL amyloidosis: a new therapeutic option? *Blood*. 2007;110:2216.
 37. Mereles D, Buss SJ, Hardt SE, et al. Effects of the main green tea polyphenol epigallocatechin-3-gallate on cardiac involvement in patients with AL amyloidosis. *Clin Res Cardiol*. 2010;99:483–490.
 38. Stefani M, Rigacci S. Beneficial properties of natural phenols: highlight on protection against pathological conditions associated with amyloid aggregation. *BioFactors*. 2014;40:482–493.
 39. Meshitsuka S, Shingaki S, Hotta M, et al. Phase 2 trial of daily, oral epigallocatechin gallate in patients with light-chain amyloidosis. *Int J Hematol*. 2017;105:295–308.
 40. Rajkumar SV, Kumar S. Multiple myeloma: diagnosis and treatment. *Mayo Clinic Proc*. 2016;91:101–119.
 41. Dispenzieri A, Buadi F, Laumann K, et al. Activity of pomalidomide in patients with immunoglobulin light-chain amyloidosis. *Blood*. 2012;119:5397–5404.
 42. Palladini G, Milani P, Foli A, et al. A phase II trial of pomalidomide and dexamethasone rescue treatment in patients with AL amyloidosis. *Blood*. 2017.
 43. Santhorawala V, Shelton AC, Lo S, et al. Pomalidomide and dexamethasone in the treatment of AL amyloidosis: results of a phase 1 and 2 trial. *Blood*. 2016;128:1059–1062.
 44. Oliva L, Orfanelli U, Resnati M, et al. The amyloidogenic light chain is a stressor that sensitizes plasma cells to proteasome inhibitor toxicity. *Blood*. 2017.
 - **In-vitro study proposing a higher sensitivity of plasma cells derived from AL patients to proteasome inhibition.**

45. Muchtar E, Gertz MA, Magen H. A practical review on carfilzomib in multiple myeloma. *Eur J Haematol.* **2016**;96:564–577.
46. Rosenthal A, Luthi J, Belohlavek M, et al. Carfilzomib and the cardiovascular system in myeloma: an endothelial effect? *Blood Cancer J.* **2016**;6:e384.
47. Muchtar E, Gatt ME, Rouvio O, et al. Efficacy and safety of salvage therapy using carfilzomib for relapsed or refractory multiple myeloma patients: a multicentre retrospective observational study. *British Journal Of Haematology.* **2016**;172:89–96.
48. Cohen AD, Landau H, Scott EC, et al. Safety and efficacy of carfilzomib (CFZ) in previously-treated systemic light-chain (AL) amyloidosis. *Blood.* **2016**;128:645–645.
49. Shirley M. Ixazomib: First Global Approval. *Drugs.* **2016**;76:405–411.
50. Merlini G, Santhorawala V, Jeffrey ZA, et al. Long-term outcome of a phase 1 study of the investigational oral proteasome inhibitor (PI) ixazomib at the recommended phase 3 dose (RP3D) in patients (Pts) with relapsed or refractory systemic light-chain (AL) amyloidosis (RRAL). *Blood.* **2014**;124:3450–3450.
51. Wechalekar AD, Schonland SO, Kastiris E, et al. A European collaborative study of treatment outcomes in 346 patients with cardiac stage III AL amyloidosis. *Blood.* **2013**;121:3420–3427.
52. Kumar S, Dispenzieri A, Lacy MQ, et al. Revised prognostic staging system for light chain amyloidosis incorporating cardiac biomarkers and serum free light chain measurements. *J Clin Oncol.* **2012**;30:989–995.
53. Dispenzieri A, Gertz MA, Kyle RA, et al. Serum cardiac troponins and N-terminal pro-brain natriuretic peptide: a staging system for primary systemic amyloidosis. *J Clin Oncol.* **2004**;22:3751–3757.
54. Gertz MA, Lacy MQ, Dispenzieri A, et al. Refinement in patient selection to reduce treatment-related mortality from autologous stem cell transplantation in amyloidosis. *Bone Marrow Transplant.* **2013**;48:557–561.
55. Kyle RA, Greipp PR. Primary systemic amyloidosis: comparison of melphalan and prednisone versus placebo. *Blood.* **1978**;52:818–827.
56. Dispenzieri A, Seenithamby K, Lacy MQ, et al. Patients with immunoglobulin light chain amyloidosis undergoing autologous stem cell transplantation have superior outcomes compared with patients with multiple myeloma: a retrospective review from a tertiary referral center. *Bone Marrow Transplant.* **2013**;48:1302–1307.
57. Golden EB, Lam PY, Kardosh A, et al. Green tea polyphenols block the anticancer effects of bortezomib and other boronic acid-based proteasome inhibitors. *Blood.* **2009**;113:5927–5937.